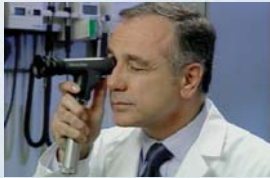


# Welch Allyn PanOptic™

## Ophthalmoscope User Guide



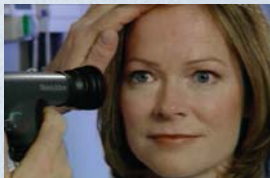### Step 1.

Remove spectacles (optional). Place the PanOptic against the brow and, using the thumb on the focusing wheel, focus on an object 3m away so that it is clear and sharp.



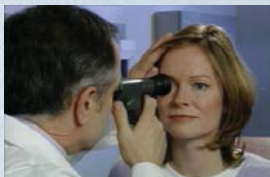### Step 2.

Using the aperture/filter dial, set to small spot (green line). Ensure that the rheostat is turned on fully. This will assist when obtaining the red reflex in step 3.



### Step 3.

Sit opposite patient and hold PanOptic 15 to 24 centimetres away, at a 15-20 degree angle on the temporal side. Look through the eyepiece until the red retinal reflex is seen.



### Step 4.

Move towards patient, following the red reflex into the pupil. To achieve the view the eyecup must contact the patient's brow.



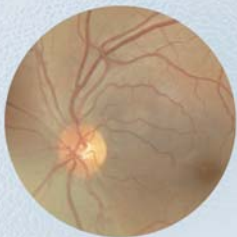### Step 5.

To maximise view compress eyecup. Maintaining contact with the patient, move the instrument to observe different areas of the fundus.

# Welch Allyn PanOptic™ Ophthalmoscope

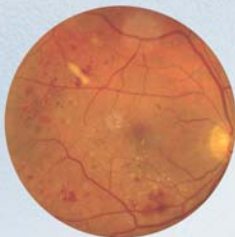

## Common appearances



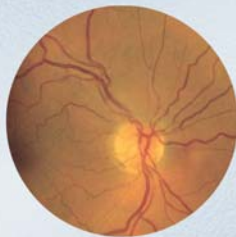### Healthy Optic Nerve

A small optic cup with pink rim tissue. The cup adheres to the ISN'T (Glaucoma) rule, with rim tissue thickest at inferior, superior and nasal portions, and thinnest at temporal.



### Nonproliferative Diabetic Retinopathy

Dot and blot haemorrhages, as well as exudates and cotton wool spots are visible in the posterior pole.



### Hypertensive Retinopathy

The arteries and veins are tortuous, with narrow arteries and arteriovenous nicking present.

Welch Allyn European Customer Services,  
Navan Business Park, Dublin Road,  
Navan, Co. Meath, Republic of Ireland  
Tel: +353 46 90 67790 Fax: +353 46 90 67754

**WelchAllyn**®

Advancing Frontline Care™

[www.welchallyn.com](http://www.welchallyn.com)

© 2007 Welch Allyn. SM3001EU Rev B